

Original Research Paper

Protective Effect of Curcumin Against Hepatic Toxicity Induced by Lithium Carbonate ($\text{Li}_2 \text{CO}_3$)

¹Gehan B.A. Youssef, ²Ahlam F. Hamoda, ³Rabab R. Elzoghby, ⁴Fatma Algendy and ⁵Shimaa A.E. Attwa

^{1,2}Department. of Forensic Medicine and Toxicology. Teaching Hospital, Faculty of Veterinary Medicine, Benha University

³Department. of Pharmacology, Faculty of Veterinary Medicine, New Valley University, Egypt

⁴Department. of Animal Wealth Improvement (Genetic and Genetic Engineering),

Faculty of Veterinary Medicine, Benha University, Egypt

⁵Department. of Biochemistry Teaching Hospital, Faculty of Veterinary Medicine, Benha University, Egypt

Article history

Received: 28-04-2019

Revised: 24-07-2019

Accepted: 30-07-2019

Corresponding Author

Gehan B.A. Youssef,
Department. of Forensic
Medicine and Toxicology.
Teaching Hospital, Faculty of
Veterinary Medicine Benha
University, Egypt
Tel: 740-597-4217
Email: Drgehan222@yahoo.com

Abstract: The current work was done on four groups of rats (10 for each) to detect the hepato-protective characters of curcumin on the toxicity induced by lithium carbonate. The oral administration of $\text{Li}_2 \text{CO}_3$ for one-month lead to noticeable decrease in the SOD, CAT and GSH while the increase in the GPx and some histological changes in the portal tissues including hydropic degeneration and thickening in the wall of the veins with numerous vacuolar degenerations were detected in most of the liver cells. Haemorrhagic, edematous blood vessels were noticed in the portal tissues. Focal areas of lymphocytic infiltration were located around the congested blood vessels and spread between the liver hepatic cords. Noticeable significant elevation of total chromosomal structure aberrations (a centaromeric, dicentric, break, fragment, deletion, sticky, end to end and ring) and total chromosomal numerical aberrations (hypoploidy, hyperploidy and polyploidy). While the pre-treatment with curcumin lead to improvement of the hepatic architecture and biochemical parameters. Also diminish of all chromosomal structure aberrations and all chromosomal numerical aberrations were noticed after treatment with curcumin. Curcumin can prevent the hazard effect of lithium carbonate on liver tissue.

Keywords: Curcumin, Hepatic Toxicity, Lithium Carbonate, Cytogenetic

Introduction

$\text{Li}_2 \text{CO}_3$ is considered monovalent cation which is used as therapeutic agent on wide range all over the world. It commonly can be valuable in dealing with depression and mental disorders (Markowitz *et al.*, 2000; Niethammer and Ford, 2007).

It also used for management and control of suicide (Cerqueira *et al.*, 2008). Although the $\text{Li}_2 \text{CO}_3$ is used for the control of psychiatric disorder, it also has harmful effect and may lead to toxicity in different organs and may cause death (Kumarguru *et al.*, 2013).

Some important studies showed that up use of $\text{Li}_2 \text{CO}_3$ as medication lead to non-curable alterations in the brain, heart and liver and this may lead to direct death in several months. (Delva and Hawken, 2001).

Lithium compound are widely used as medication in different forms although its dangerous side effects on the general health (Kielczykowska *et al.*, 2006).

The effect of $\text{Li}_2 \text{CO}_3$ on the kinetics of the antioxidant enzymes was studies in blood and tissues.

It has no significant changes on glutathione peroxidase (GPx) and superoxide dismutase (SOD) and also on malonyldialdehyde concentration in blood. It causes diminishes in the kinetics of the enzymes in tissues, highly detected in liver (SOD) and kidney (GPx and SOD).

The $\text{Li}_2 \text{CO}_3$ had no detectable effect on lipid peroxidation in tissues (Kielczykowska *et al.*, 2006). It also had detectable reduction in reduced glutathione, SOD, CAT, GSH, GPX activities, and parallel diminish in ATP in rat tissues. The total lipids, and fatty acids in hepatic tissues were elevated in abnormal manner due to lithium carbonate toxicity.

Curcumin is now days used as important element in the structure of compound or single medication for the control of inflammatory disorders especially in hepatic tissues, since it has powerful effects on the body immunity and is a powerful inhibitor of different reactive oxygen-generating enzymes (Araujo and Leon 2001; Chainani, 2003).

Materials and Methods

Drugs and Chemicals

Li₂ Co₃ (Prianil CR): Commercial drugs widely used in Egypt as tablets. Each tablet contains 400 mg of Li₂ Co₃. Produced by the Nile Company (Cairo, Egypt). The recommended dose was dissolved in 20 ml distilled water.

Curcumin: The curcumin powder was used in the current work which was extracted from the turmeric roots by acetone solvent according to (Tonnesen, 2002)

Experimental Protocol

Animal experiments were done following guidelines set by Ethical Committee of Benha University. The rats were divided into 4 groups, each of 10 rats:

- I. Group: Rats were given distilled water and normal saline orally by intra-gastric gavage for (30 days)
- II. Group: Rats were given curcumin orally at doses (150 mg/kg body weight/day) dissolved in 0.5 ml of 10% DMSO according to (ElMackawy and Sharaf 2006)
- III. Group III: Rats were given (150 mg/kg b.wt/ day.) of Li₂ Co₃ orally (Vijaimohan *et al.*, 2010) which was dissolved in distilled water for 30 days and were sacrificed after 24 hrs of last dose. This dose was toxic for rats.
- IV. Group IV: Rats were given curcumin (150 mg/kg b.wt./day) orally 1 hour before the dose of Li₂ Co₃ as group III daily for 30 days

After the end of the experiment, the hepatic tissue was collected and kept in 10% neutral buffered formalin for histological preparations according to (Bancroft and Gamble, 2008). The hepatic tissue sample was kept for biochemical analysis. The bone marrow of the femurs bone was prepared for cytogenetic materials.

Genotoxic Studies (Chromosomal Aberration)

According to (Alder, 1984) all rats were prepared for IP injection by colchicine 4 mg/kg bwt. After 2 hours of injection rats were scarified, then dissect femurs bone and flush bone marrow by normal saline in centrifuge tube which centrifuged at 1000 rpm for 300 sec, then decant supernatant. Add sufficient amount of hypotonic potassium chloride (KCL 0.56% solution) at 37C° to each tube and kept in the incubator in degree similar to room temperature for 10 min then centrifuged and decant the supernatant.

The sediment was fixed by methanol (cold): acetic acid glacial (3:1), the fixation was repeated twice time with 10 minutes interval, the last fixation for 30 minutes at 4°C then centrifuged and decant supernatant. Pellets were re-putted in fresh fixative solution. Dropping 2-3 drops of the content by paster pipette on clean cold glass slides in a distance more than 50cm length and placed on warmer slid for drying then stained with 5% Geimsa stain according to the appropriate time and washed by distilled water, left to dry. These slides were examined by oil immersion microscope lens to determine structural and numerical aberration for each rat according to (Ogo *et al.*, 1996).

Determination of Catalase (CAT) Activity

CAT activity (in U/g tissue) was assessed liver homogenate by the method of (Aebi, 1984).

Determination of Glutathione

Total glutathione level was measured enzymatically in the liver tissue by a slightly modified method of (Mangino *et al.*, 1991).

GSH (reduced glutathione) levels were quantified by the method of (Moron *et al.*, 1979). The absorbance of the solutions were estimated at 412 nm against blank. The level of ATP in the heart tissue was determined by the method of (Ryder, 1985).

Estimation of Antioxidant Enzymes (SOD)

The activity of superoxide dismutase (SOD) was measured according to (Marklund and Marklund, 1974).

Statistical Analysis

The data were analyzed by Bartlett's test for equal variance and by Gaussian-shaped distribution for normality using the Kolmogorov-Smirnov goodness-of-fit test. As the data passed the normality test ($p > 0.001$), group means were compared with the ANOVA with post hoc testing using Tukey-Kramer Multiple Comparisons Test. All results were expressed as means \pm SEM and the significance were defined as $p < 0.001$ for all tests.

Results

The antioxidant activities of the liver were decreased in the lithium carbonate administered group compared to the control as shown in (Table 1). Pretreatment with curcumin lead to improve in the antioxidant defense mechanism enzyme in compare to the third group. While in the second group (Curcumin) no significant changes in the enzyme activity in compare to the first group (Control).

Table 1: Antioxidants Enzymes activities in liver tissue

	SOD	CAT	GSH	GPx
Control	7.51± 0.36	3.81±0.19	4.99±0.02	0.02±0.002
Curcumin	7.64± 0.41	3.83±0.31	5.01±0.04	0.02±0.001
Lithium	5.51± 0.32*	2.98±0.15*	2.99±0.02*	0.05±0.004
Lithium+ curcumin	7.17± 0.35a	3.01±0.23a	3.79±0.04a	0.03±0.001a

SOD: Superoxide dismutase (u/g); CAT: Catalase (u/g); GSH-reduced glutathione - mg of GSH/mg protein. GPx- Glutathione peroxidase: U/mg. These values were appeared as significant difference at *P ,0.001 as compared with first control group; significant difference at aP ,0.001 as compared with second group (lithium carbonate group)

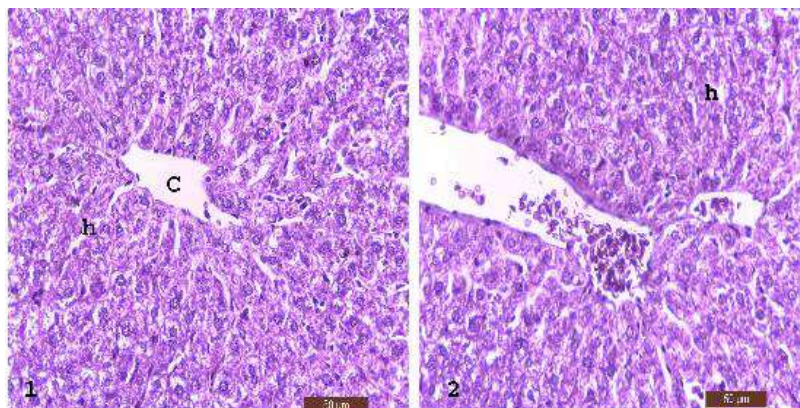


Fig. 1 and 2: Photomicrograph of the liver tissue showing normal structure of the hepatic tissue; central vein (C) and hepatic cords (h) H&E

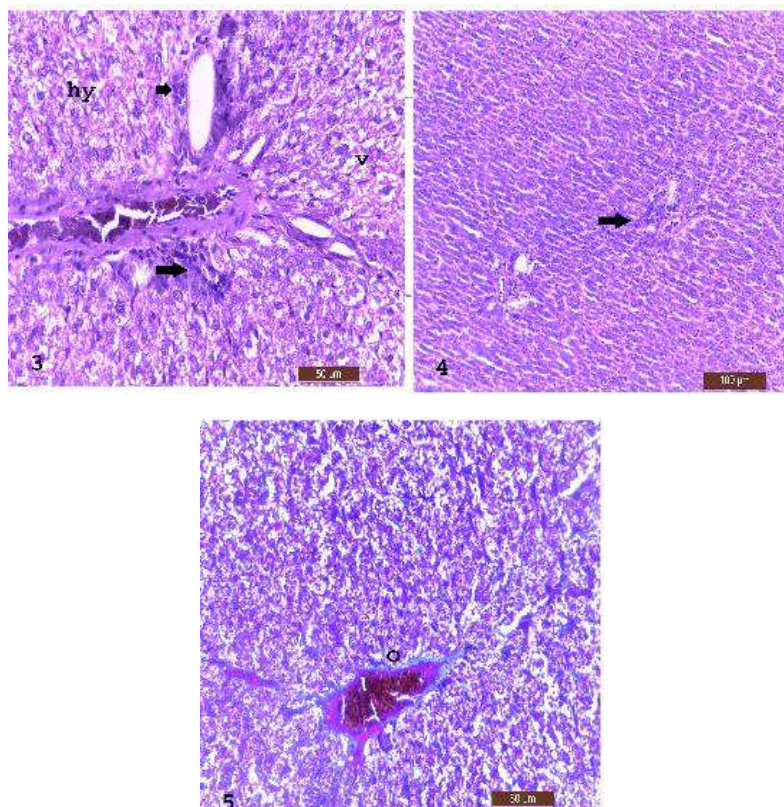


Fig. 3, 4 and 5: The third group had numerous histopathological changes as minutes vacuoles (v) hydropic degeneration (hy) thick wall blood vessels (arrow), Focal areas of lymphocytic infiltration (arrow), Some blood vessels showed edema and thickening their walls (o) H&E

Histopathological Findings

The liver of the control group consisted of hepatic cords with central vein. The hepatocytes were consisted of polygonal cells with prominent nuclei which had basophilic stain and acidophilic stained cytoplasm (Fig. 1). The liver tissue of the second group had well developed hepatic cords (Fig. 2). The hepatocytes of the lithium carbonate administered group were filled with minutes vacuoles as hydropic degeneration and thickening in the wall of the veins with numerous vacuolar degenerations were noticed in most of the hepatocytes. congested blood vessels (Fig. 3). Focal areas of lymphocytic infiltration were located around the congested blood vessels and spread between the hepatic cords (Fig. 4). Hepatic blood vessels showed edema and thickening their walls (Fig. 5). The liver of the treated group showed regeneration in the cells of the hepatic

cords and some hepatocytes still suffered from vacuolar degeneration (Fig. 6).

Genotoxic (Chromosomal Aberrations) Studies

Prominent significant elevation of total chromosomal structure aberrations (a centromeric, dicentric, break, fragment, deletion, sticky, end to end and ring) and total chromosomal numerical aberrations (hypoploidy, hyperploid and polyploidy) in group III (Lithium Carbonate only) in relation to the control one, group II (Curcumin only) and group IV treated with (Lithium Carbonate and Curcumin). While prominent significant decrease of total chromosomal structure aberrations and total chromosomal numerical aberrations in group II (Curcumin only) and group IV treated with (Lithium Carbonate and Curcumin) than group III (Lithium Carbonate only) (Figs. 7, 8, 9, 10, 10a, 11 and 12).

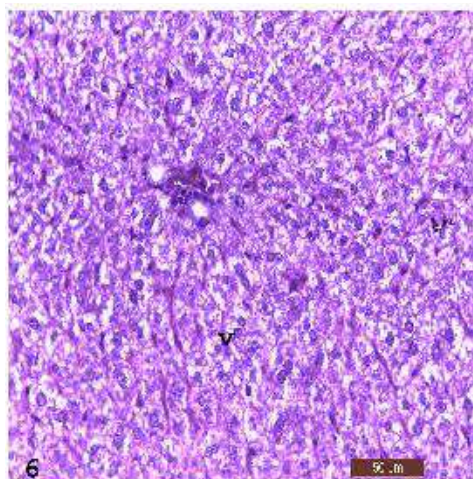


Fig. 6: The treated group showed improvement in the architecture of the hepatic tissue although some hepatocytes showed vacuolar degeneration (v) H&E. Scale bar.50

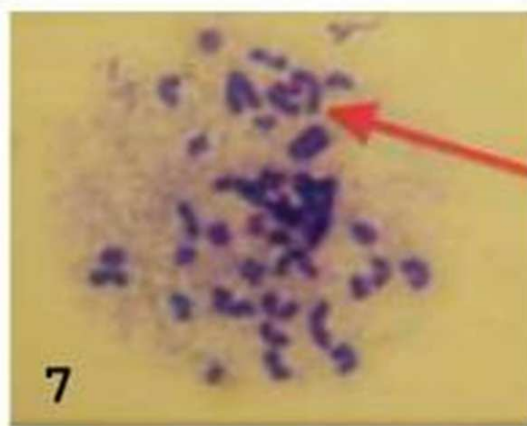


Fig. 7: Meta phase spread shown structural chromosomal aberration in rats treated with Lithium (arrow) end to end aberration

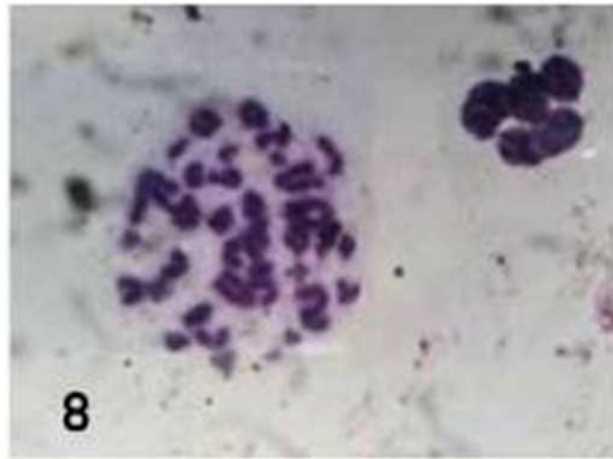


Fig. 8: Meta phase spread shown structural chromosomal aberration in rats treated with Lithium ring aberration

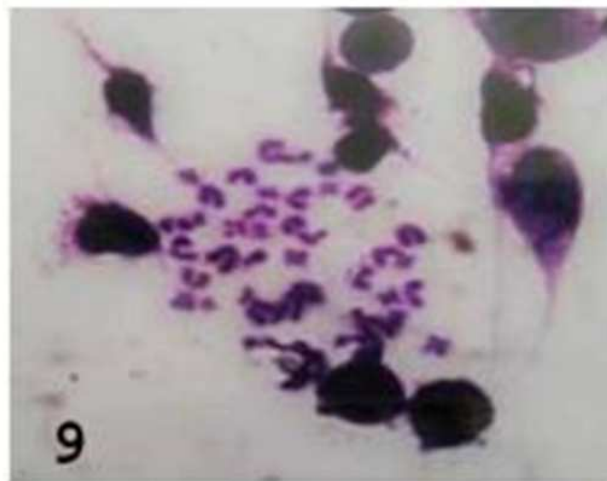


Fig. 9: Meta phase spread shown structural chromosomal aberration in rats treated with Lithium (fragment and) deletion aberration

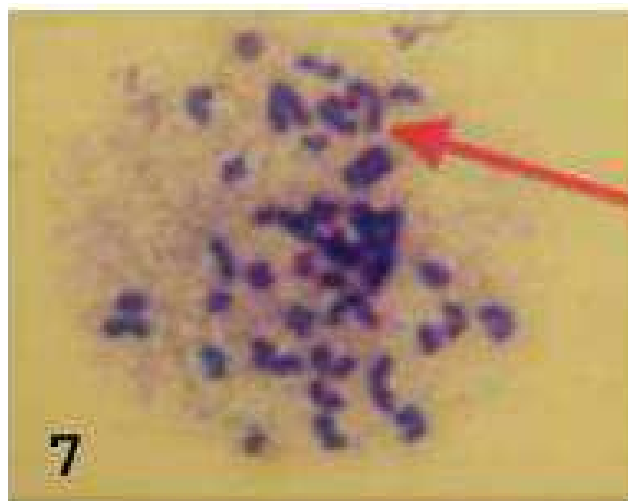


Fig. 7: Meta phase spread shown structural chromosomal aberration in rats treated with Lithium (arrow) end to end aberration

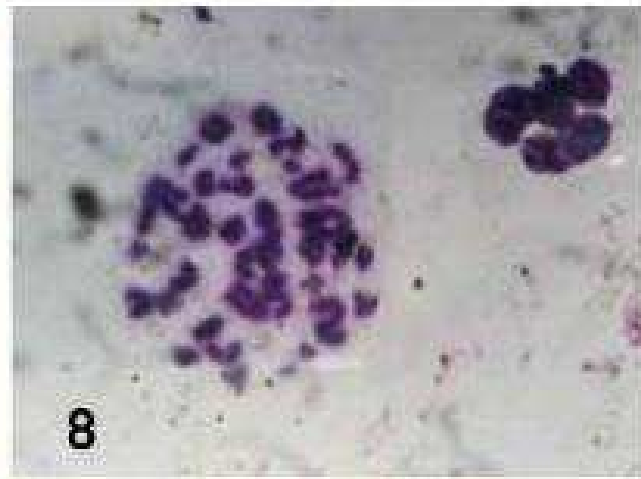


Fig. 8: Meta phase spread shown structural chromosomal aberration in rats treated with Lithium ring aberration

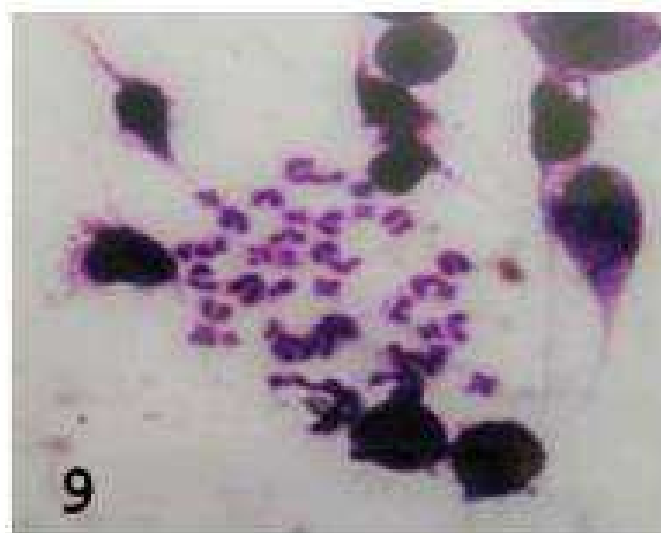


Fig. 9: Meta phase spread shown structural chromosomal aberration in rats treated with Lithium (fragment and) deletion aberration

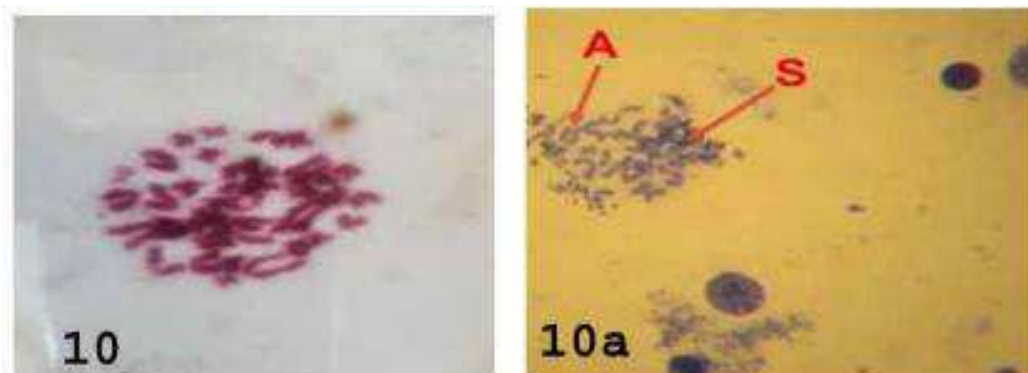


Fig. 10 and 10a: Meta phase spread shown structural chromosomal aberration in rats treated with Lithium (A) a centromericattenuation and (S) sticky aberrations

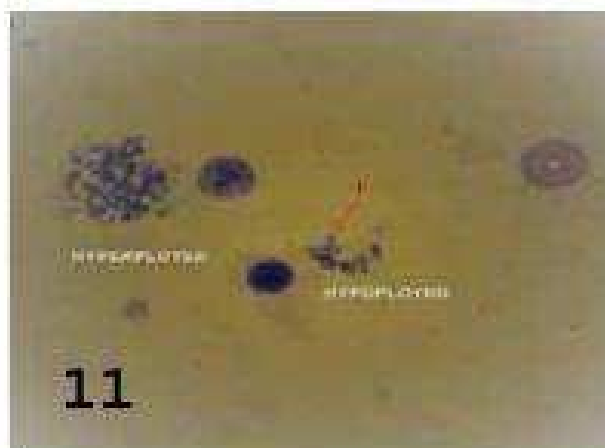


Fig. 11: Meta phase spread shown numerical chromosomal aberration in rats treated with Lithium Hypoploid and Hyperploid aberrations

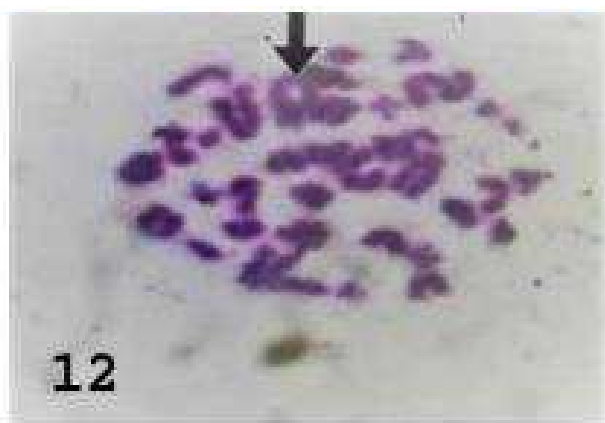


Fig. 12: Meta phase spread shown structural chromosomal aberration in rats treated with Lithium break aberration

Discussion

Our findings showed the use of lithium carbonate as medication lead to hepatic toxicity and the liver tissues showed numerous histopathological alterations. These findings were augmented by the results of. (Bhat *et al.*, 2014), Shah *et al.*, 1995; Sharief *et al.*, 2011). While the liver of patients had oral over dose of lithium carbonate showed increase level of serum aminotransferases, with minimal hepatic hazard effects. The histopathology findings showed no hepatic injury or other alterations including jaundice (Mcknelly *et al.*, 1970).

The oxidative stress was initiated after lithium toxicity which direct lead to increase lipid peroxidation. SOD and catalase enzymes characterized by decreased their levels in the tissue (Tandon *et al.*, 1998).

The curcumin, because it has potent antiinflammatory (Bereswill *et al.*, 2010), antioxidant properties (Al-Jassabi *et al.*, 2012), antimicrobial activity (Tajbakhsh *et al.*, 2008), antiviral activity (Kutluay *et al.*, 2008), anticarcinogenic

(Das and Vinayak, 2012) and anti-diabetic (Aziz *et al.*, 2013) effects, so it used for the cure of hepatic disorders including injury due to toxicity (Altenburg *et al.*, 2001; Chattopadhyay *et al.*, 2004).

Both of carbon tetrachloride and aflatoxin B caused intensive damage to the hepatic tissue (Morsy *et al.*, 2012; El-Agamy, 2010 respectively). So, it was discovered that the curcumin had protective effect on liver tissues (Jobin *et al.*, 1999). Also the curcumin has silymarin like action (Girish, 2009) which lead to prevention the hepatic injury (Li *et al.*, 2013) via inhibition of MAO-A enzyme in hepatic tissue (Yu *et al.*, 2002).

Curcumin is considered one of the powerful scavenger of (ROS) reactive oxygen species including superoxide anion radicals and hydroxyl radicals. Curcumin played an fundamental role in inhibition of blood (Erythrocyte) lipid peroxidation during the process of inflammation (Borra *et al.*, 2013). Also, it prevents the creation of free radicles which has harmful role in myocardial ischemia and paraquat

induced lung injury in rats (Manikandan *et al.*, 2004; Venkatesan, 2000). Also, curcumin protected blood, liver, and erythrocyte in response to diazinon- toxicity in Wistar rats (Messarah *et al.*, 2013).

Regarding to the effect of lithium carbonate on the chromosomes revealed prominent increase of total chromosomal structure aberrations and total chromosomal numerical aberrations in group III in comparison with control one, group II and group IV. Our studies are in confirmation with those of (Rafael *et al.*, 1976) where in the chromosome breakdown caused by lithium carbonate was dose dependent. Srivastava *et al.* (1986) recorded that chromosomal damages caused by Lithium Carbonate was due to breaks and fragmentations of DNA. Moreover, that Lithium could have several ways of acting on DNA as Li binds selectively to DNA (Kuznetsov *et al.*, 1971) as it competes with Mg²⁺ leading to impairment on DNA synthesis (Becker and Tyobeka, 1990) and DNA repair.

While in group II and group IV than group III our result showed that significant decrease of total chromosomal structure aberrations and total chromosomal numerical aberrations which agree with Treshiama *et al.*, 1998; Petr *et al.*, 2006), where they explain the anti-mutagenic effect of curcumin against different mutagenic agents, as they found administration of antioxidants inhibited the breakdown of DNA strand induced by lithium Carbonate toxicity.

Conclusion

The lithium carbonate was toxic to the hepatocytes when used as medication for depression but the addition of curcumin as replacement medication can ameliorate the hazard effect of lithium carbonate

Acknowledgement

The authors want to introduce deep gratitude to the staff of the department of forensic medicine and teaching hospital staff for their support and advice. Also, many thanks to the central laboratory of the college of veterinary medicine Benha University.

Author's Contributions

Gehan Youssef: Contributed in proposal writing, final report, performance of scientific comments and publishing the paper.

Ahlam Hamouda: Contribute in preparing the extract, review articles and interpretation the cytogenetics

Rabab Elzoghby: Contributed in proposal writing, drugs preparation and final report.

Fatma Elgendy: Contributed in design of the experiment, performance of the scientific comments and interpretation the cytogenetics.

Shimaa Attwa: Contributed in biochemical analysis, final report and performance of static analysis.

Conflict of Interests

The authors declare that there is no conflict of interests regarding the publication of this paper.

References

- Aebi, H., 1984. *Methods Enzymol.* 105: 121-126.
DOI: 10.1016/S0076-6879(84)05016-3
- Alder, L., 1984. *Cytogenetic testes in mammals.* Venitts. Parry J. *Mutagenicity Testing: A practical Approach*, IRL Press. Oxford, pp: 273-306.
- Al-Jassabi, S., K.A Ahmed and M. Ameen, 2012. Antioxidant effect of curcumin against microcystin-LR-induced renal oxidative damage in Balb/c mice. *Trop J. Pharm. Res.* DOI: 10.4314/tjpr.v11i4.2
- Altenburg, J.D., A.A. Bieberich, C. Terry, K.A. Harvey and J.F. Vanhorn *et al.*, 2001. Biological activities of curcuma longa L. *Memories Institute Oswaldo Cruz*, 96: 723-728.
DOI: 10.1590/S0074-02762001000500026
- Araujo, C.C. and L.L. Leon, 2001. Biological activities of curcuma longa L. *Memories Instituto Oswaldo Cruz*, 96: 723-728.
DOI: 10.1590/S0074-02762001000500026
- Aziz, M.T, I.N. El-Ibrashy, D.P. Mikhailidis, A.M. Rezaq and M.A. Wassef *et al.*, 2013. Signaling mechanisms of a water soluble curcumin derivative in experimental type 1 diabetes with cardiomyopathy. *Diabetol Metab Syndr*, 5: 5-13.
DOI: 10.1186/1758-5996-5-13
- Bancroft, J.D. and M. Gamble, 2008. *Theory and Practice of Histological Techniques*, 6th Edn. Philadelphia: Churchill Livingstone Elsevier, 67: 126-127. DOI: 10.1097/NEN.0b013e31817e2933
- Becker, R.W. and E.M. Tyobeka, 1990. Lithium enhances proliferation of HL60 promyelocytic leukemia cells. *Leukemia Res.*, 14: 879-884.
DOI: 10.1016/0145-2126(90)90177-B
- Bereswill, S., M. Munoz, A. Fischer, R. Plickert and L. Haag *et al.*, 2010. Anti-inflammatory effects of resveratrol, curcumin and simvastatin in acute small intestinal inflammation. *PLoS One*.
DOI: 10.1371/journal.pone.0015099
- Bhat, G.h.M., N.A. Shah, S. Shadad, M. Saleem Ito and B.A. Shah *et al.*, 2014. Lithium carbonate induced Histological changes in the Liver of Albino Rats. *J. Pharmacy Biol. Sci.*, 9: 45-48.
DOI: 10.9790/3008-09314548

- Borra, S.K., P. Gurumurthy, M. Mahendra, K.M. Jayamathi and C.N. Cherian *et al.*, 2013. Antioxidant and free radical scavenging activity of curcumin determined by using different in vitro and ex vivo models. *J. Med. Plants Res.*, 7: 2680-2690.
- Cerqueira, A.C., M.C. Reis, F.D. Novis, J.M. Bezerra and G.C. Magalhaes *et al.*, 2008. Cerebellar degeneration secondary to acute lithium carbonate intoxication. *Arq Neuropsiquiatr*, 66: 578-80.
DOI: 10.1590/S0004-282X2008000400032
- Chainani-Wu, N., 2003. Safety and anti-inflammatory activity of curcumin: A component of tumeric (*Curcuma longa*). *J. Alternative Complementary Med.*, 9: 161-168.
DOI: 10.1089/107555303321223035
- Chattopadhyay, I., K. Biswas, U. Bandyopadhyay and R.K. Banerjee, 2004. Turmeric and curcumin: Biological actions and medicinal applications. *Curr. Sci.*, 87: 44-53.
- Das, L. and M. Vinayak, 2012. Anti-carcinogenic action of curcumin by activation of antioxidant defence system and inhibition of NF-KB signalling in lymphoma bearing mice. *Bio. sci. Rep.*, 32: 161-170. DOI: 10.1042/BSR20110043
- Delva, N.J. and E.R. Hawken, 2001. Preventing lithium intoxication. *Guide for physicians. Canadian Family Phy.*, 47: 1595-1600.
- El-Agamy, D.S., 2010. Comparative effects of curcumin and resveratrol on aflatoxin B (1)-induced liver injury in rats. *Arch. Toxicol.*, 84: 389-396.
DOI: 10.1007/s00204-010-0511-2
- ElMackawy, A. and H.A. Sharaf, 2006. Cytogenetical and histochemical studies on curcumin in male rats. *WIT Transactions Bio. Health*, 10: 169-180.
DOI: 10.2495/ETOX060171
- Girish, C., B.C. Koner, S. Jayanthi, K. Ramachandra Rao and B. Rajesh *et al.*, 2009. Hepatoprotective activity of picroliv, curcumin and ellagic acid compared to silymarin on paracetamol induced liver toxicity in mice. *Fundam Clin Pharmacol.*, 6: 735-745. DOI: 10.1111/j.1472-8206.2009.00722. x
- Jobin, C., C. Braham, M.P. Russo, B. Juma and A.S. Narula *et al.*, 1999. Curcumin blocks cytokine-mediated NF- κ B activation and proinflammatory gene expression by inhibiting inhibitory factor I- κ B kinase activity. *J. Immunol.*, 163: 3474-3483.
- Kielczykowska, M., K. Pasternak, I. Musik, J. Wrońska-Tyra and A. Hordyjewska, 2006. The influence of different doses of lithium administered in drinking water on lipid peroxidation and the activity of antioxidant enzymes in rats. *Polish J. Environ. Stud.*, 15: 747-751.
- Kumarguru, B.N., M. Natarajan and A.H. Nagarajappa, 2013. Pathology of lithium induced nephropathy: A Case Report and Review, with Emphasis on the Demonstration of Mast Cells. *J. Clinical Diagnostic Res.*, 7: 374-377.
- Kutluay, S.B, J. Doroghazi, M.E. Roemer and S.J. Triezenberg, 2008. Curcumin inhibits herpes simplex virus immediate-early gene expression by a mechanism independent of p300/CBP histone acetyltransferase activity. *Virology*, 373: 239-247.
DOI: 10.1016/j.virol.2007.11.028
- Kuznetsov, I.A., A.S. Lukanin and L.F. Tsurkanov, 1971. Effect of ions of the alkaline metals on the secondary structure of DNA. IV. Thermal denaturing deoxyribonucleates of alkaline metals in solution with a low ionic strength. *Biofizika*, 16: 144-145.
- Li, G., J.B. Chen, C. Wang, Z. Xu and H. Nie *et al.*, 2013. Curcumin protects against acetaminophen-induced apoptosis in hepatic injury. *World J. Gastroenterol.*, 19: 7440-7446.
DOI: 10.3748/wjg.v19.i42.7440
- Mangino, M.J., M.K. Murphy and G.G. Glabar, 1991. Protective effects of glycine during hypothermic renal ischemic reperfusion injury. *Am. J. Physiol.*, 261: F841-F848.
DOI: 10.1152/ajprenal.1991.261.5. F841
- Manikandan, P., M. Sumitra, S. Aishwarya, B.M. Manohar and B. Lokanadam *et al.*, 2004. Curcumin modulates free radical quenching in myocardial ischaemia in rats. *Int. J. Biochem. Cell Biol.*, 36: 1967-1980. DOI: 10.1016/j.biocel.2004.01.030
- Marklund, S. and G. Marklund, 1974. Involvement of the superoxide anion radical in the autoxidation of pyrogallol and a convenient assay for superoxide dismutase. *Eur. J. Biochem.*, 47: 469-74.
DOI: 10.1111/j.1432-1033.1974.tb03714.x
- Markowitz, G.S., J. Radhakrishnan, N. Kambham, A.M. Valeri and W.H. Hines *et al.*, 2000. lithium nephrotoxicity: A progressive combined glomerular and tubulointerstitial nephropathy. *J. Am. Soc. Nephrol.*, 11: 1439-48.
- McKnelly, W.V.Jr., J.P. Tupin and M. Dunn, 1970. Lithium in hazardous circumstances with one case of lithium toxicity. *Compr. Psychiatry*, 11: 279-86.
DOI: 10.1016/0010-440X(70)90175-6
- Messarrah, M., W. Amamra, A. Boumendjel, L. Barkat and I. Bouasla *et al.*, 2013. Ameliorating effects of curcumin and vitamin E on diazinon-induced oxidative damage in rat liver and erythrocytes. *Toxicol. Ind. Health*, 29: 77-88.
DOI: 10.1177/0748233712446726
- Moron, M.S, J.W. Depierre and B. Mannervik, 1979. Levels of glutathione, glutathione reductase and glutathione-S-transferase activities in rat lung and liver. *Biochem. Biophys. Acta*, 582: 67-72.
DOI: 10.1016/0304-4165(79)90289-7

- Morsy, M.A, A.M. Abdalla, A.M. Mahmoud, S.A. Abdelwahab and M.E. Mahmoud, 2012. Protective effects of curcumin, α -lipoic acid, and N-acetylcysteine against carbon tetrachloride-induced liver fibrosis in rats. *J. Physiol. Biochem.*, 68: 29-35.
DOI: 10.1002/mds.21318
- Niethammer, M. and B. Ford, 2007. Permanent lithium induced cerebellar toxicity: Three cases and review of literature. *Mov. Disord.*, 22: 570-3.
DOI: 10.1016/0955-2863(95)00181-6
- Ogo, Y., T. Kasai and S. Kiviyama, 1996. Vitamin E prevents the elevation of thiobarbituric acid reactive substances but not hemolytic anemia in rats fed excess methionine. *Japan. Nutr. Biochem.*, 7: 77-84.
DOI: 10.1016/0955-2863(95)00181-6
- Rafael, D.L.T., E. Krompotic and L. Kowlessard, 1976. The in vivo and in vitro effects of lithium on human chromosomes and cell replication view issue *TOC. Teratol.*, 13: 131-138.
DOI: 10.1002/tera.1420130203
- Ryder, J.M., 1985. Determination of adenosine triphosphate and its breakdown products in fish muscle by high performance liquid chromatography. *J. Agri. Food Chem.*, 33: 678-80.
DOI: 10.1021/jf00064a027
- Shah, M.S and G. Hassan, 1995. Effects of Lithium on histology of kidney, liver, Spleen and Skin of Rat. *JK Practitioner*, 2: 174-175.
- Sharief, N., A. Rabia, O. Iftikhar, 2011. Adverse effects of withdrawal of chronic lithium therapy on liver-a histological study. *Pakistan J. Zool.*, 43: 1155-80.
- Srivastava, S., A. Sharma and G. Talukder, 1986. Effects of lithium carbonate on cellular systems in mice. *Persp. Cytol. Genetics*, 5: 381-386.
- Tajbakhsh, S., K. Mohammadi, I. Deilami, K. Zandi and E. Ramedani *et al.*, 2008. Antibacterial activity of indium curcumin and indium diacetylcurcumin. *Afr. J. Biotechnol.*, 7: 3832-3835.
- Tandon, A., D.K. Dhawan, J.P. Nagpaul, 1998. Effect of lithium on hepatic lipid peroxidation and antioxidative enzymes under different dietary protein regimens. *J. Applied. Toxicol.*, 18: 87-90.
DOI: 10.1002/(Sici)1099- 63(199805/06)18:3<187:: Aid-Jat495>3.0.CO;2-Y
- Tonnesen, H.H., 2002. Solubility, chemical and photochemical stability of curcumin in surfactant solution. *Pharmazie*, 57: 820-824.
- Treshiama, K.C., J. George and R. Kuttan, 1998. Protective effect of curcumin, ellagic acid and bixin on radiation induced genotoxicity. *J. Exp. Clinical Cancer Res.*, 17: 431-434.
- Venkatesan, N., 2000. Pulmonary protective effects of curcumin against paraquat toxicity," *Life Sciences*, vol. 66, no. 2, pp. 21-82. DOI: 10.1016/S0024-3205(99)00576-7
- Vijaimohan, K., J. Mallika and C.S. Shyamala Devi, 2010. Chemoprotective effect of sobatum against lithium-induced oxidative damage in rats. *J. Young Pharm.*, 2: 68-73. DOI: 10.4103/0975-1483.62217
- Yu, Z.F, L.D. Kong and Y. Chen, 2002. Antidepressant activity of aqueous extracts of *Curcuma longa* in mice. *J. Ethnopharmacol.*, 83: 161-165.
DOI: 10.1016/S0378-8741(02)00211-8