

Original Research Paper

Sialoliths: A Radiographic Retrospective Study

¹Georges Aoun, ²Abbass El-Outa and ¹Ibrahim Nasseh

¹Department of Oral Medicine and Maxillofacial Radiology,
Faculty of Dental Medicine, Lebanese University, Beirut, Lebanon

²Department of Emergency Medicine, American University of Beirut, Beirut, Lebanon

Article history

Received: 29-11-2020

Revised: 03-02-2021

Accepted: 06-02-2021

Corresponding author:

Georges Aoun

Department of Oral Medicine
and Maxillofacial Radiology,
Faculty of Dental Medicine,
Lebanese University, Beirut,
Lebanon

Email: dr.georgesoun@gmail.com

Abstract: Sialoliths are salivary gland calcifications that mainly affect submandibular and parotid glands. They are detected incidentally on dental panoramic radiographs. This study aimed to determine the prevalence of sialoliths in a Lebanese sample and evaluate the site, gender and age distribution of such findings. In this retrospective study, 500 digital panoramic radiographs, belonging to 219 males and 281 females aged 18-88 years, were examined to identify sialoliths seen as radiopacities in the parotid, submandibular and sublingual glands regions. Findings were analyzed statistically using IBM SPSS Statistics for Windows, version 20 (IBM Corp., Armonk, N.Y., USA). Descriptive statistics were presented and Chi-square tests and Spearman correlation coefficient were used to assess relationships between sialoliths and gender, age and site. Statistical significance was set at $p = 0.05$. In our sample of 500 radiographs, sialoliths were identified in 15 (3%). Submandibular sialoliths were the most common (1.8%) followed by parotid sialoliths (1.2%); no sublingual sialoliths were detected. Females were slightly more affected by submandibular sialoliths while males had higher prevalence of parotid sialoliths. No significant age or gender predilections were detected. Identifying sialoliths on panoramic radiographs by dental professionals is essential to avoid possibility of confusion with other soft tissue calcifications very common in the head and neck regions.

Keywords: Sialolith, Salivary Gland, Panoramic Radiograph

Introduction

As the most common salivary gland disorder, sialolithiasis is a condition in which calcifications or calculi (sialoliths) form inside salivary glands or in their ductal system (Delli *et al.*, 2014; de Oliveira Capote *et al.*, 2015). Sialolithiasis may affect any salivary gland; however, studies report that sialoliths most commonly arise in submandibular glands, followed by the parotid glands. Sialolithiasis may remain asymptomatic for long or cause pain and swelling which may eventually progress into sialadenitis promoted by salivary flow obstruction (Bar *et al.*, 2007).

Sialoliths are among the soft tissue calcifications that may be detected on routine panoramic radiography (Freire *et al.*, 2019). Few studies investigated sialoliths using 2 D and 3 D imaging; they report a prevalence ranging between 0.01 and 3%. Similarly, autopsy studies reported 1-2% prevalence (Schroeder *et al.*, 2011).

Indeed, due to the fact that such calcifications may be confused with other radiopacities found incidentally in the same regions (Garay *et al.*, 2014; Ribeiro *et al.*, 2018; Kamikawa *et al.*, 2006; Berticelli *et al.*, 2018), it is imperative that dental professionals are aware of such entities and able to readily identify them when examining dental panoramic radiographs.

Consequently, in this study we aim to evaluate the prevalence of sialoliths as detected on panoramic radiographs in a sample of Lebanese adults. Moreover, we study the distribution and locations of such calcifications along with their clinical implications.

Materials and Methods

In this cross-sectional retrospective study, we assessed archived digital panoramic radiographs of Lebanese adult patients taken initially for diagnostic dental indications in the Department of Maxillofacial

Radiology at the Lebanese University, Faculty of Dental Medicine in Beirut, Lebanon.

During their initial visit, all patients provided their informed consent for anonymous research use as per the Faculty regulations; radiographs of those who did not consent were not added to the radiological archive.

All the panoramic radiographs included in our study were taken with the digital Pax-Zenith® panoramic unit (Vatech, Korea). Unit settings were set based on patient profile (60-90 kV, 6-10 mA) and exposure time was 10-20 sec.

Images of low quality, as well as those with missing age and/or gender were excluded from the study.

Eventually, a series of 500 digital panoramic radiographs were included in our study comprising 219 males and 281 females aged 18-88 years (mean of 47.9 ± 19

years). The images were examined by an experienced maxillofacial radiologist using the same monitor over a period of 5 sessions separated by 15-day period.

The examination was repeated after two weeks blinded to the primary examination results to reduce detection and entry error.

Sialoliths were identified as radiopacities located in the sublingual, submandibular and parotid regions (Fig. 1).

Data entry and analyses were performed using IBM SPSS Statistics for Windows, version 20 (IBM Corp., Armonk, N.Y., USA). Descriptive statistics were presented as frequency and percentage for cases and gender and mean \pm standard deviation for age. Chi-square tests and Spearman correlation coefficient were used to assess relationships. Statistical significance was set at $p = 0.05$.

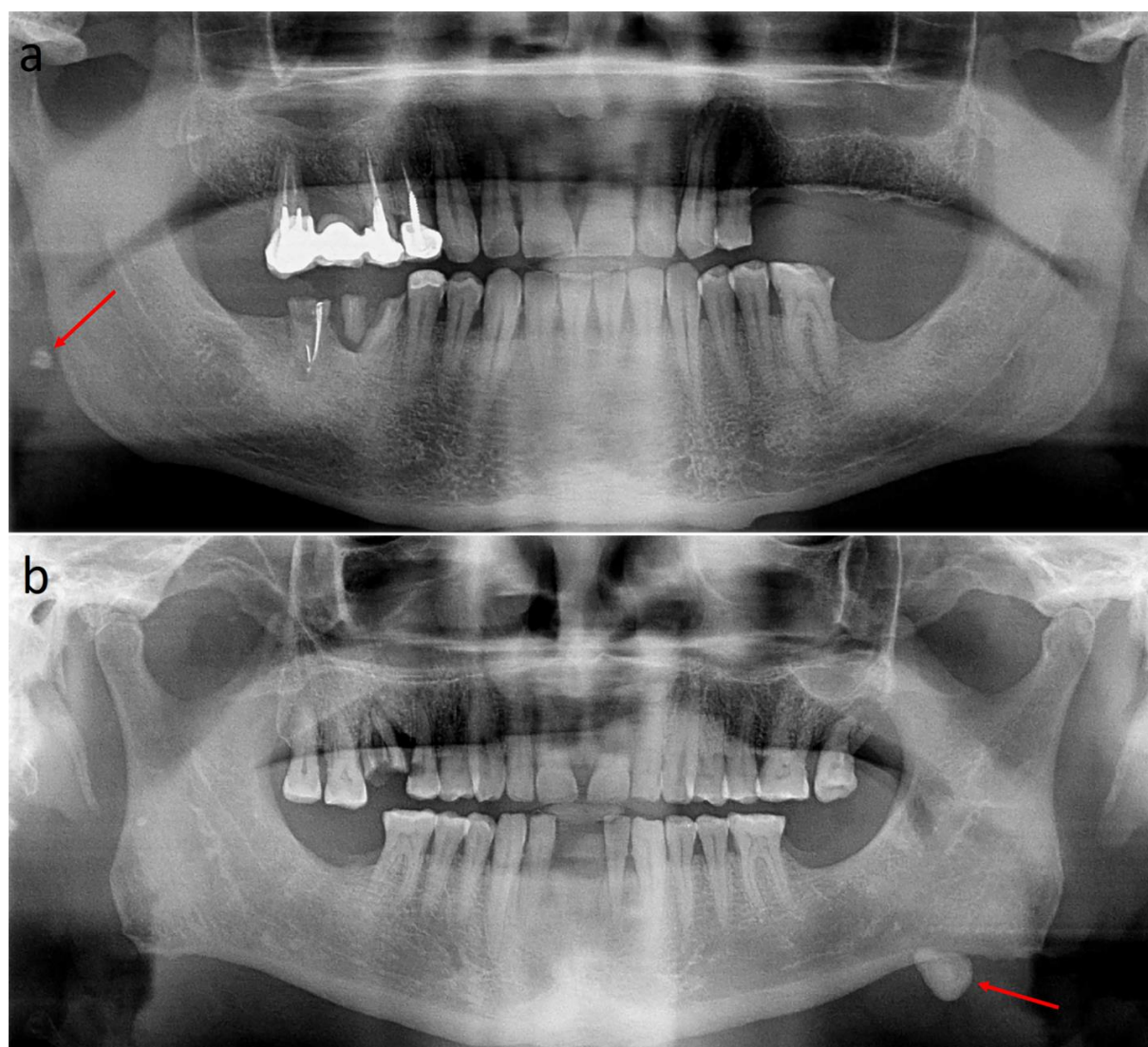


Fig. 1: Panoramic radiographs showing parotid (a) and submandibular (b) sialoliths (red arrows)

Results

In our sample of 500 panoramic radiographs, sialoliths were detected in 15 (3%). Parotid sialoliths were seen in 6 cases (1.2%) (2/281 females and 4/219 males) (Fig. 2); among these, 4 cases (1 female and 3 males) were on the left side, one female's case was on the right side and one male's case was bilateral (Table 1).

On the other hand, submandibular sialoliths were found in 9 cases (1.8%) (7/281 females and 2/219 males) of the study population (Fig. 2); among these, 7 cases (6 females and 1 male) were on the right side, one female's case on the left side and one male's case was bilateral (Table 1).

Unsurprisingly, no sublingual sialoliths were found.

There were no significant associations between genders and both parotid and submandibular sialoliths, although females were more affected by submandibular sialoliths and less affected by parotid sialoliths than males (Fig. 2).

In our study, the mean ages of patients affected with parotid and submandibular sialoliths were 61.1 years (ranging from 44 to 75 years) and 60.2 years (ranging from 42 to 87 years) respectively (Figs. 3 and 4). There was no significant age predominance.

Discussion

Salivary gland sialoliths are detectable on routine dental panoramic radiographs. Several other authors attempted to evaluate the incidence of sialoliths on routine imaging. In a recent study with a large sample, (Berticelli *et al.*, 2018) examined 2444 panoramic radiographs and calculated an incidence of sialoliths of 1.96%. Kaswan *et al.* (2014) studied the prevalence of submandibular sialoliths using periapical and occlusal radiographs and found that 5 of their 196 subjects (2.5%) suffer from submandibular sialoliths, higher than that in our study (1.8%). Similarly, (Vengalath *et al.*, 2014) determined a prevalence of submandibular sialoliths of

4.3% in their sample of 1615 panoramic radiographs, divided equally between males and females.

In another recent study, (Icoz and Akgunlu, 2019) stated a prevalence of 1% of sialoliths with males slightly more than females.

On the other hand, other studies reported significantly lower prevalence. MacDonald and Yu (2020) recently studied panoramic radiographs for incidental findings and found that only 0.1% sialoliths were detected. Conversely, the prevalence of submandibular sialoliths reported by (Sutter *et al.*, 2018) was 0.9%. Furthermore, in their sample, (Ariayi *et al.*, 2009) described a prevalence of submandibular sialoliths of 0.2%, but with marked male predominance (male to female ratio of 1:3).

In our study, submandibular gland was mostly affected, followed by the parotid gland. No sublingual sialolith were detected. This is in line with previous reports that showed predominance of sialoliths to the submandibular gland and extremely rare sublingual sialoliths (de Oliveira Capote *et al.*, 2015; Missias *et al.*, 2018; Schreiner-Tiefenbacher *et al.*, 2019; Schröder *et al.*, 2017).

To our knowledge, this is the first study to report on the prevalence of sialoliths in Lebanon and among the few worldwide. Nevertheless, given the relatively low prevalence of sialoliths, future studies should comprise a larger sample size to allow better evaluation of the relation between sialoliths and demographic parameters.

Table 1: Gender and site distribution of sialoliths

	Submandibular		Parotid		Total
	Male	Female	Male	Female	
<i>Left</i>	0	1	3	1	5
<i>Right</i>	1	6	0	1	8
<i>Bilateral</i>	1	0	1	0	2
<i>Total</i>	2	7	4	2	15

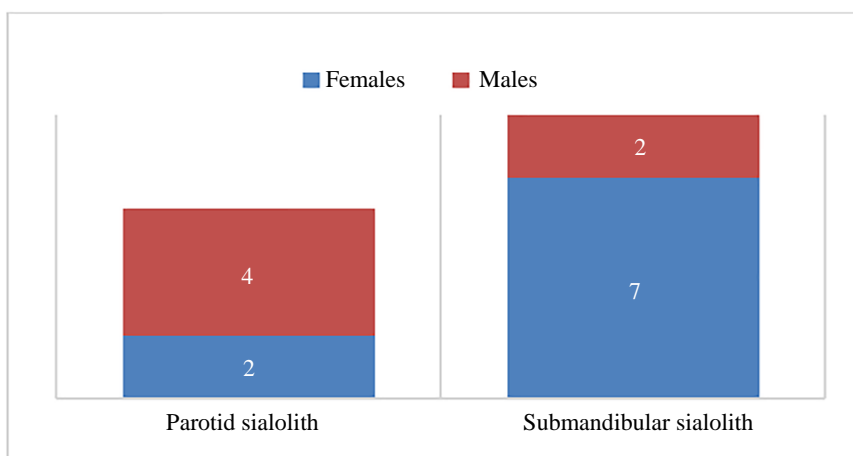


Fig. 2: Gender distribution of parotid and submandibular sialoliths in our sample

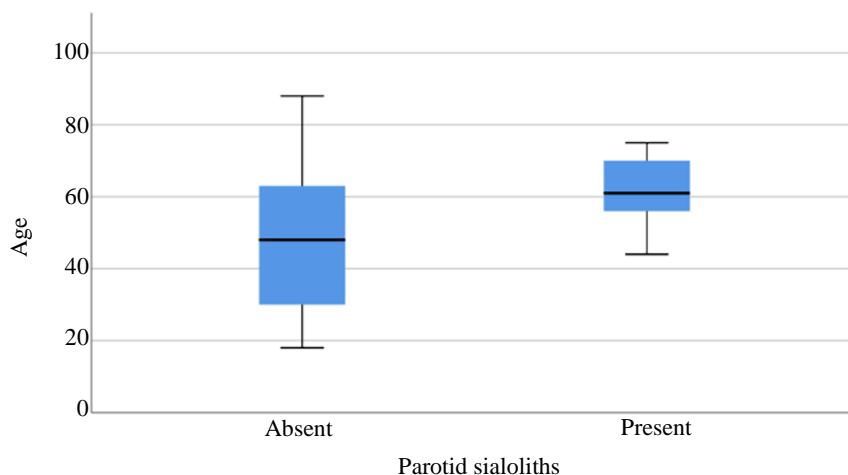


Fig. 3: Chart showing the correlation age-parotid sialoliths in our sample

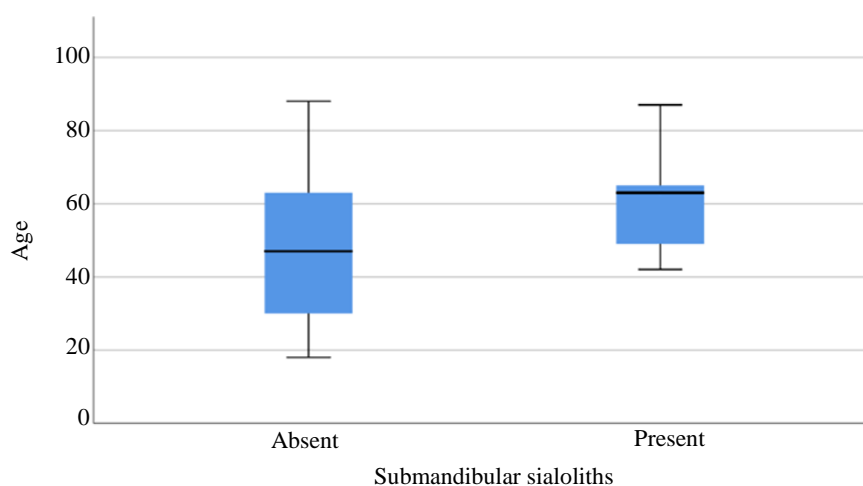


Fig. 4: Chart showing the correlation age-submandibular sialoliths in our sample

Conclusion

Salivary gland sialolithiasis is not an uncommon condition that may result in pain, swelling and subsequent infection. Our study prevalence was in line with reported range and site. Given the usefulness of panoramic radiography in detecting sialoliths, dental professionals should be well aware of the condition and able to identify and differentiate it from other soft tissue calcifications.

Authors Contribution

Ibrahim Nasseh: Performed the assessment.

Abbass El-Outa: Performed the data analysis and helped writing the manuscript.

Georges Aoun: Designed and directed the project and wrote the paper. Performed the assessment

Ethics

This article is original and contains unpublished material. The corresponding author confirms that all of the other authors have read and approved the manuscript and no ethical issues involved.

References

- Ariayi, A. S., Berndt, D., & Lambrecht, J. T. (2009). Soft tissue calcifications in panoramic radiography. A risk factor for cerebrovascular accidents? *Schweizer Monatsschrift fur Zahnmedizin = Revue mensuelle suisse d'odonto-stomatologie = Rivista mensile svizzera di odontologia e stomatologia*, 119(10), 1009-1013.
- Bar, T., Zagury, A., London, D., Shacham, R., & Nahlieli, O. (2007). Calcifications simulating sialolithiasis of the major salivary glands. *Dentomaxillofacial Radiology*, 36(1), 59-62.

- Berticelli, R. S., Conci, R. A., Togashi, A., Gadonski, A. P., & Popiolek, I. M. (2018). Calcifications in soft tissues observed in panoramic radiographs. *EC Dental Science*, 17(11), 2012-2018.
- de Oliveira Capote, T. S., de Almeida Gonçalves, M., Gonçalves, A., & Gonçalves, M. (2015). Panoramic radiography—diagnosis of relevant structures that might compromise oral and general health of the patient. *Emerging Trends in Oral Health Sciences and Dentistry*. 733-762.
- Delli, K., Spijkervet, F. K., & Vissink, A. (2014). Salivary gland diseases: infections, sialolithiasis and mucocoeles. *Saliva: Secretion and Functions*, 24, 135-148.
- Freire, J. L., França, S. R., Teixeira, F. W., Fonteles, F. A., Chaves, F. N., & Sampieri, M. B. (2019). Prevalence of calcification of the head and neck soft tissue diagnosed with digital panoramic radiography in Northeast Brazilian population. *Minerva stomatologica*, 68(1), 17-24.
- Garay, I., Netto, H. D., & Olate, S. (2014). Soft tissue calcified in mandibular angle area observed by means of panoramic radiography. *International journal of clinical and experimental medicine*, 7(1), 51-56.
- Icoz, D., & Akgunlu, F. (2019). Prevalence of detected soft tissue calcifications on digital panoramic radiographs. *SRM Journal of Research in Dental Sciences*, 10(1), 21-25.
- Kamikawa, R. S., Pereira, M. F., Fernandes, Â., & Meurer, M. I. (2006). Study of the localization of radiopacities similar to calcified carotid atheroma by means of panoramic radiography. *Oral Surgery, Oral Medicine, Oral Pathology, Oral Radiology and Endodontology*, 101(3), 374-378.
- Kaswan, S., Patil, S., Maheshwari, S., Rahman, F., & Khandelwal, S. (2014). The relationship between pulp calcifications and salivary gland calcifications. *Journal of clinical and experimental dentistry*, 6(5), e474-478.
- MacDonald, D., & Yu, W. (2020). Incidental findings in a consecutive series of digital panoramic radiographs. *Imaging science in dentistry*, 50(1), 53-64.
- Missias, E. M., Nascimento, E. H. L., Pontual, M. L. A., Pontual, A. A., Freitas, D. Q., Perez, D. E. C., & Ramos-Perez, F. M. M. (2018). Prevalence of soft tissue calcifications in the maxillofacial region detected by cone beam CT. *Oral diseases*, 24(4), 628-637.
- Ribeiro, A., Keat, R., Khalid, S., Ariyaratnam, S., Makwana, M., do Pranto, M., Albuquerque, R., & Monteiro, L. (2018). Prevalence of calcifications in soft tissues visible on a dental pantomogram: A retrospective analysis. *Journal of stomatology, oral and maxillofacial surgery*, 119(5), 369-374.
- Schreiner-Tiefenbacher, B., Forster, V., Pauli, K., Sutter, W., Meier, M., Roland, H., Bandura, P., & Turhani, D. (2019). Evaluation of mandibular calcification on 3D volume images. *Heliyon*, 5(5), e01698.
- Schrøder, S. A., Andersson, M., Wohlfahrt, J., Wagner, N., Bardow, A., & Homøe, P. (2017). Incidence of sialolithiasis in Denmark: a nationwide population-based register study. *European Archives of Oto-Rhino-Laryngology*, 274(4), 1975-1981.
- Schroeder, M. A., Schroeder, D. K., Santos, D. J. S., & Leser, M. M. (2011). Molar extractions in orthodontics. *Dental Press Journal of Orthodontics*, 16 (6), 130-157.
- Sutter, W., Berger, S., Meier, M., Kropp, A., Kielbassa, A. M., & Turhani, D. (2018). Cross-sectional study on the prevalence of carotid artery calcifications, tonsilloliths, calcified submandibular lymph nodes, sialoliths of the submandibular gland and idiopathic osteosclerosis using digital panoramic radiography in a Lower Austrian subpopulation. *Quintessence International*, 231-242.
- Vengalath, J., Puttabuddi, J. H., Rajkumar, B., & Shivakumar, G. C. (2014). Prevalence of soft tissue calcifications on digital panoramic radiographs: A retrospective study. *Journal of Indian Academy of Oral Medicine and Radiology*, 26(4), 385-389.