

Original Research Paper

# Albusite: A Novel Synthetic Gel for Promotion of Skin Wound Healing in Rats

<sup>1</sup>Shahram Jahanabadi, <sup>2</sup>Mohammad Yasin Karami, <sup>3</sup>Shahram Paydar, <sup>4</sup>Hamid Farzinnia, <sup>5</sup>Mohamed Amin Ghobadifar, <sup>6</sup>Nasrin Mansournia and <sup>7</sup>Mehrnoosh Maalagh

<sup>1,2,3</sup>Trauma Research Center, Shahid Rajaei Hospital, Shiraz University of Medical Sciences, Shiraz, Iran

<sup>4</sup>Department of Veterinary, School of Veterinary, Shiraz University of Medical Sciences, Shiraz, Iran

<sup>3</sup>Zoonoses Research Center, Jahrom University of Medical Sciences, Jahrom, Iran

<sup>6</sup>Metabolic Disease Research Center, Faculty of Medicine, AJA University of Medical Sciences, Tehran, Iran

<sup>7</sup>Student Research Committee, Jahrom University of Medical Sciences, Jahrom, Iran

## Article history

Received: 08-12-2014

Revised: 01-04-2015

Accepted: 18-06-2015

Correspondence Author:

Shahram Paydar

Faculty of Medicine, Shiraz

University of Medical

Sciences, Rajaei Trauma

Hospital, Chamran Street,

Shiraz, Fars, Iran

Tel :+98-71-3625-4206

Fax: +98-71-3625-4206

E- mail: paydarsh@gmail.com

**Abstract:** The current study was performed to evaluate the effect of Albusite gel on the healing process of excisional wounds in diabetic and control rats. Fifty-two Sprague Dawley male rats were used to evaluate the effects of Albusite Gel (synthetic gel) on the healing of full-thickness skin wounds. The control group (n = 26) and study group (n = 26) were divided into two groups (n = 13). Wounds were assessed by wound measurements and collection of samples at 9 (A, C) and 21 days (B, D) post-wounding to evaluate the healing process. Variables of interest were gross and microscopic histopathological characteristics were reflective of wound healing. Topical Albusite gel was applied for wound A and B, once a day. Each rat was anesthetized and a round full thickness excisional wound with 150 cm<sup>2</sup> area was performed on the right dorsolateral side of each rat. There was little difference between the case and control groups. Wound healing processes and wound closure in the intervention group began sooner and completed more quickly respectively, but both of them did not show a statistically significant difference (p>0.05). The healing of Albusite treated wound was better than the control wounds grossly. The study wounds were biopsied at days 9 and 21, so this might not show different effects of the Albusite gel group in appropriate time. Therefore, further studies are recommended with more sample size and less biopsy interval.

**Keywords:** Albusite Gel, Sprague Dawley Rat, Wound Healing

## Introduction

A wound represents a disturbance of the normal arrangement and functions of the skin and soft tissue structure and may be due to a variety of mechanisms and etiologies. Atiyeh *et al.* (2002; Gross, 2000) the clinical assessment of wounds begins with a determination of whether the wound is acute or chronic in nature. Acute wounds are those in which healing is anticipated to progress through an orderly physiological chain of inflammation, proliferation and maturation. Schultz *et al.* (2003; Broughton *et al.*, 2006) When this process is altered or started, a chronic wound may develop and is more likely to occur in patients with underlying disorders such as peripheral artery disease, diabetes, venous insufficiency, nutritional deficiencies and other disease states. A chronic wound may be defined as one that is physiologically impaired because of inadequate angiogenesis, impaired innervations, or impaired cellular

migration among other reasons. Golinko *et al.* (2009) Examples of chronic wounds include ischemic ulcers, venous ulcers, neuropathic foot ulcers and infected wounds including surgical site infections. Brem *et al.* (2000; 2003) to ensure proper healing, the wound bed needs to be well vascularized, free of devitalized tissue, clear of infection and moist. Wounds that demonstrate progressive healing as evidenced by granulation tissue and epithelialization can undergo closure or coverage. Many topical agents and alternative therapies are available that are meant to improve the wound healing environment and although data are lacking to support any definitive recommendations, some may be useful under specific circumstances.

Albusite gel is a synthetic gel (based on an ointment used empirically in Iranian traditional medicine) provided by one of the researchers on the study with seven years' experience in chronic wounds and has

gradually been completed and tested over repeated experiments and studies on some limited survey. But it is necessary to be examined in academic studies and if this is confirmed, it may be a new hope in treatment of chronic wounds, especially diabetic foot ulcers and bed sores. Compounds used in the gel-based are those suggested in textbooks of pharmacology, surgery and internal medicine for wound healing. Because the gel is not registered yet, the exact composition cannot be publicized. But its contents are growth factor, antibiotic ointment, an agent causing inflammation, an underlying gelatinous substance, natural deodorant and some other materials such as propylene glycol.

Propylene glycol is widely used in pharmaceutical industry, food and cosmetic ingredients, topical emollient, especially as a solvent and carrier materials that are unstable or insoluble in water and also as a stabilizer in vitamin compounds. The use of this material is either systemical or local. The systemic use is rapidly absorbed from the gastrointestinal tract and topical form absorbed by damaged skin. Lactate and pyruvate in the liver are metabolized to the substance and excreted in the urine. Sweetman (2009) side effects of topical use of propylene glycol are limited and rare and include the following: Local irritation (especially in the case of impermeable dressings or used on mucous membranes), poisoning (if used on burn wounds) and hypersensitivity reaction (Sweetman, 2009; Lessman *et al.*, 2005). Bacterial colonization and infection disrupts wound healing, especially chronic wounds. White *et al.* (2001; Lipsky and Hoey, 2009) topical application of antibiotic substances may help the wound to heal (Diehr *et al.*, 2007; Gethin, 2009; Dai *et al.*, 2010).

The possible mechanism of induction of wound healing with Albusite gel prompted us to design this study survey the effect of Albusite gel on the healing process of excisional wounds in diabetic and control rats.

## Methods

### Experimental and Animals

Male Sprague Dawley (albino) rats (300-400 gr) aged 3 months old were used. The animals were housed in standard environmental conditions of temperature (23±30C), humidity (60±15%) and a 12 h light/dark cycle for at least 7 days before use. During the experiment, the rats were given the standard pellet diet (Shiraz University of Medical Sciences Animal Laboratory, Iran) and water. All the procedures were approved by the Medical Ethics Committee of Shiraz University of Medical Sciences.

### Wound Healing Activity

The dorsal skin of the Sprague Dawley rats was shaved before the beginning of the excision wound

healing experiments. Animals were anesthetized with intra-peritoneal Ketamine (sigma Aldrich, United States of America, 80 mg/kg) and Xylazine (sigma Aldrich, United States of America, 3 mg/kg). One full-thickness excision wound (circular area about 150 mm<sup>2</sup> and 2 mm depth) was created along the markings using eye surgery punchers about 12 mm in diameter (corresponding to the Albusite Gel treatment in Group A and B, saline treatment in Group C and D per rat).

The 52 rats were divided randomly into four groups of thirteen rats (A and B as the experimental groups with 9 and 21 days follow up, respectively and also C and D as the control group of group A and B, respectively). POD 9, 21 refers to the day that histology sample was taken from the corresponding group of rats in both experimental and control cases. Each rat had one wound that was treated topically with Albusite Gel as the experimental run in A and B groups, sterile Saline as the control in C and D groups, respectively (Fig. 1 and 2).

The wound area of each rat was photographed during the wound healing period on days 0 (onset of wound surgery), 4, 9 in group A and C and days 0, 4, 9, 14, 21 in Group B and D. The wound area was calculated using Adobe Photoshop CS (version 5) software. Electro-Cardiogram (ECG) paper was used for reference scale.

The percentage of wound closure was calculated as follows using the initial and final area during the: (Lansky and Newman, 2007):

$$[\% \text{ of wound closure} = (\text{wound area on day } 0 - \text{wound area on day } N) / \text{wound area on day } 0 \times 100]$$

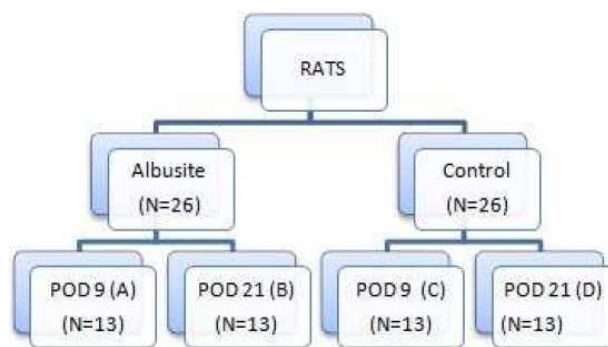


Fig. 1. The randomization flow chart

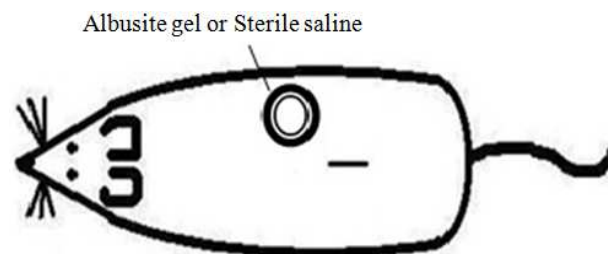


Fig. 2. Schematic figure of rat wound

“N” in the above formula is the day on which the photograph is taken. N = Days 4, 9 for A and C groups and Days 4, 9, 14 and 21 for B and D groups. The wound area was removed with 2 mm safe margin from the surviving animals for histopathological examination. The excision skin biopsies of the wound of each rat were fixed in 10% formaldehyde solution.

### Histological Grading

The samples were immediately fixed in formalin, embedded in paraffin, sectioned and stained with Hematoxylin and Eosin (H and E) and Masson’s trichrome method at a magnification of  $\times 100-400$ . We used the Abramov’s histological scoring system and M. Stacie Scardino study (Abramov *et al.*, 2007; Scardino *et al.*, 2002). Abramov’s system assessed each parameter independently and gave it a score of 0-3 (absent=0, Slight=1, moderate=2, extensive=3).

### Statistical Analysis

The results were expressed as mean  $\pm$  Standard Deviation (SD). The relative wound area was statistically analyzed, using Repeated Measurement ANOVA. Histopathological analysis for comparing the materials with each other and also in different days was performed using Mann-Whitney U test. Differences were considered statistically significant in the case  $p < 0.05$ . All statistical analyses were performed using Statistical Package for Social Sciences, version 15.0 (SPSS Inc., Chicago, IL, USA).

## Results

The mean area  $\pm$  standard deviation of the wounds treated by Albusite Gel in both groups ( A and B) was not significantly lower than the control wounds that were treated with normal saline C and D ( $p > 0.05$ ) (Table 1). The wound closure was began sooner and earlier in the cases group compared to the control groups but the difference was not statistically significant over time ( $p > 0.05$ ) (Table 2 and Fig. 3).

Histopathology results of the wounds treated with Albusite gel of Group A showed less tissue necrosis and higher inflammation, granulation tissue formation and neovascularization than the control group (C) that were treated with normal saline. Also, the level of re-epithelialization, collagen deposition and hemorrhage were similar to the control group. Also, the biopsy of the wounds treated by Albusite gel of the 21 day follow up group (B) showed less fibroblast proliferation and level of re-epithelialization, inflammatory infiltrates, granulation tissue and collagen deposition were similar to the control wounds (Table 3). There was no

statistically significant relationship of wound area and closure between the case and control groups except day 21 in group B, but faster full wound closure was reported in B group compared to the controls.

Albusite treated group A showed more fibroblast proliferation (11-30) on day 9 in 30.8% compared to 0% in the control group C and a significant fibroblastic proliferation showed a statistically significant relationship (predominantly fibroblasts ( $>30$ )) in 69.2% of group A wounds versus 100% of the control group C.

Table 1. The mean and standard deviation of wound areas of the groups

Treatment days	Wound area means and $\pm$ SD		
	A	C	P value
0	170.79 $\pm$ 14.77	165.14 $\pm$ 19.19	0.177
4	97.36 $\pm$ 27.25	104.15 $\pm$ 33.23	0.387
9	19.46 $\pm$ 9.4	25.9 $\pm$ 13.42	0.344
	B	D	
0	168.21 $\pm$ 14.16	160.21 $\pm$ 15.79	0.98
4	91.16 $\pm$ 22.03	101.96 $\pm$ 17.39	0.57
9	21.10 $\pm$ 10.29	27.83 $\pm$ 9.49	0.31
14	0.57 $\pm$ 1.02	1.08 $\pm$ 1.16	0.55
21	0.0 $\pm$ 0.00	0.26 $\pm$ 0.49	<0.001

A: Albusit gel treated wounds with 9 days follow up, B: Albusit gel treated wounds with 21 days follow up, C: Sterile saline treated wounds with 9 days follow up, D: Sterile saline treated wounds with 21 days follow up

Table 2. The percentage of wound closure in each group

Treatment groups	Photograph capture day			
	4 (%)	9 (%)	14 (%)	21 (%)
A	42.99	88.6		
C	36.93	84.3		
B	45.80	87.45	99.66	100.0
D	36.35	82.62	99.30	99.8

A: Albusit gel treated wounds with 9 days follow up, B: Albusit gel treated wounds with 21 days follow up C: Sterile saline treated wounds with 9 days follow up, D: Sterile saline treated wounds with 21 days follow up

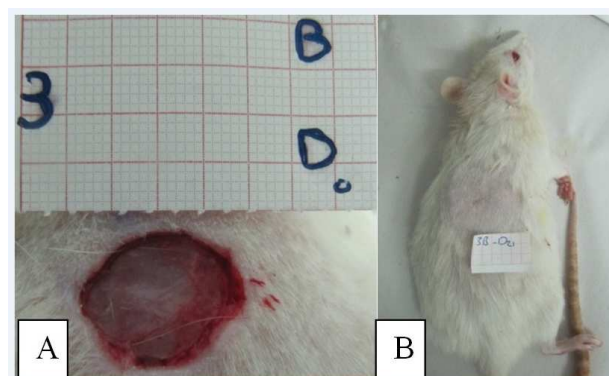


Fig. 3. Wound healing in Albusite treated Rat D0: The wound of one of Experimental rat in begin D21: Treated wound of same rat after 21 days in Experimental rat

Table 3. Histopathology results of wounds treated with Albusite gel and control sterile saline

Histopathological criteria survey									
Wound	Neovascularization	Necrosis	Hemorrhage	Fibroblast proliferation	Inflammatory infiltrates	Granulation tissue	Collagen deposition	Reepithelialization	
A	+++	-	+	+++	+++	++	+	+	
C	++	-/+	+	+++	++	+	+	+	
B	+	-	-/+	++	+	+++	+++	+++	
D	+	-	-/+	+++	+	+++	+++	+++	

+:Slight, ++: Moderate, +++: Extensive, -: Absent

A: Albusit gel treated wounds with 9 days follow up, B: Albusit gel treated wounds with 21 days follow up C: Sterile saline treated wounds with 9 days follow up, D: Sterile saline treated wounds with 21 days follow up

Also, 23.1% of Albusite wounds (group B) showed increased fibroblast proliferation and predominant fibroblastic proliferation (61.5% in Group Albusite (B) compared to 100% of the control group (D)) showed a statistically significant relationship ( $p < 0.05$ ). The rate of mild granulation tissue (46.2% in Group Albusite (A) vs. 53.8% of control (C)) and moderate granulation tissue (53.8% in Group A vs. 38.5% of controls (a)) did not show a statistically significant relationship on day 9 ( $p > 0.05$ ).

Mild tissue necrosis in biopsy specimens groups a (7.7 %) and C (30.8%) on day 9, respectively. Also, there was no tissue necrosis in 92.3% of the group a samples whereas no tissue necrosis was observed in only 69.2% of the slides in the control group (C). Both groups' biopsies (intervention and control) had no necrosis on day 21. The difference between the amount of inflammation, tissue necrosis, hemorrhage, collagen deposition, granulation tissue maturation, epithelialization and neovascularization of the intervention groups and control groups of the 9 day and 21 day follow up groups was not significant ( $P$ -value= 0.33). But the difference in fibroblast proliferation was statistically significant between the cases and control groups ( $P$ -value=0.015).

## Discussion

Albusite gel obtained from the combination of growth factor, antibiotic ointment, an agent causing inflammation, an underlying gelatinous substance, natural deodorant and some other materials such as propylene glycol was prepared and used for wound healing activities. Wound healing is a biological process from the onset of injury up to scar formation and it is a dynamic process in which cellular, biochemical and physiological events occur (Atiyeh *et al.*, 2002; Gross, 2000). Although individual tissues may have unique healing characteristics, all tissues heal by similar mechanisms and the process undergoes phases of inflammation, cellular migration, proliferation, matrix deposition and remodeling (Brunicardi *et al.*, 2009).

Traditionally, different topical materials have been used to heal the wounds better, such as local honey, tragacanth and egg (Hojati *et al.*, 2004). This topical extract and ointment may have bacterial anti-proliferation effects but also cause fibroblast and

keratinocyte proliferation phase arrest and wound healing delay. Silver sulfadiazine induced less epithelialization witch has important roles in full thickness (McCauley *et al.*, 1994).

When the ideal wound healing occurs, inflammation process, hemorrhage, neovascularization and fibrosis start faster and finally less hemorrhage, inflammation, neovascularization and tissue necrosis are detected. Also, the wound shows more mature granulation tissue, more collagen and diffuse alignment and complete epithelialization (Kumar *et al.*, 2005). If the wound is injured in the course of fibrosis, it is very susceptible to scar formation and there is not a balance between collagenase and collagen synthesis, so maturation phenomenon is not induced and if the wound has more granulation formation, it means the wound healing starts but it is delayed or stops in this phase. Moreover, if no granulation tissue is seen, it means the wound has (Kumar *et al.*, 2005).

Albusite gel formula belongs to one of the project partners and is used clinically for poor end stage chronic diabetic and bed ulcers at list of amputation after taking consent of them. So far, there has been no previous experimental study conducted on Albusite wound healing effect. In the study of wound healing activity of neomycin-Ghee Combination, the wounds were biopsied on day 10 (Atiyeh *et al.*, 2002), so the author decided to do wound biopsy on days 9 and 21. Derici *et al.* (2010) showed in their study that the neovascularization score of the wounds treated with sildenafil was 1.5 on the 7th day while the control group had a score of 1.0. Neovascularization was higher in the intervention group on the 21st day (1.7 against 1.0). However, they found no significant difference regarding the epithelialization between the two groups (Derici *et al.*, 2010). The wound in the Albusite treated group started the inflammatory process faster and more potent and passed quickly to low inflammation at the end but it there was no significant difference between the two groups in each wound biopsy on days 9 and 21. The absence of tissue necrosis was reported in diabetic wound healing study done by Malava Sylvestris on days 9 and 18 compared to the mild to moderate tissue necrosis of the control group (Pirbalouti *et al.*, 2010).

The present study shows moderate to severe tissue necrosis in either of the groups. It can be said that if the biopsy was prepared in the early days of the study, it was

more likely to be visible. Although the difference in tissue necrosis of the ninth day wound biopsy was not significant, lower levels of tissue necrosis may intervene in favor of the effectiveness of the Albusite gel but further studies are needed to confirm it. The study of fibroblast proliferation shows few fibroblasts (3-10) and none to minimal fibroblasts (<3) in all groups (except for fibroblast proliferation of group B) was zero percent.

The results of present study clearly indicate that fibroblast proliferation in the control group was more than Albusite treated group on the ninth and 21st days; this is expected because using topical antibiotics on rat skin wounds in another study reduces wound closure (Leitch *et al.*, 1993). In the study of Nisbet and colleagues (Murphy and Evans, 2012), the effects of 3 different kinds of honey were examined on cutaneous wound healing in rabbits; the mean fibroblast proliferation on days 7, 14 and 21 in the control group was lower than that of the intervention group.

In the wounds that have more fibroblast formation at the end of wound healing period, the risk of fibrosis and scar formation is increased and there is no balance between collagen synthesis and collagenase. This problem has been seen in the control group; on the other hand, it is possible that the intervention group results (lower level of proliferation of fibroblasts) confirm the faster process of wound healing. In this case, it is expected that wound healing is improved in the early stages of fibroblast proliferation in the intervention group than the control group. The scar formation in treatment group was reduced. As in previous cases, it seems that we need a biopsy on days closer to zero, so we can demonstrate faster wound healing in the intervention group.

The biopsy between days 9 and 21 (i.e., on days 12, 14 or 15 and 18) can more accurately determine the healing process. In a study conducted by Dericci and colleagues, the inflammation score of wounds treated with sildenafil was 2.3 on the 7th day while wounds of the control group had a higher score of 2.5. At the end of the 21st day, acute inflammation was a little higher in the control group (0.5 against 0.7) (Dericci *et al.*, 2010). There is no significant difference of neovascularization and epithelialization between groups in comparison with Drici's Study (Dericci *et al.*, 2010). Another study compared the effects of three types of honey on the treatment of rabbit skin wounds. The mean fibrosis level of the control group was less than the intervention groups on the 7th, 14th and 21st days. Only three out of eight rabbits of the group treated with pure rhododendron honey had complete epithelialization and mature granulation while other groups were not totally epithelialized (Murphy and Evans, 2012). All the wounds of the intervention groups were completely epithelialized on the 21st day.

Granulation consists of fibroblast, endothelial cells and (Stadelmann *et al.*, 1998; DiPietro, 2013).

There was no mild to moderate granulation tissue in Both Groups (B, D), so all of them had mature granulation tissue. Most of the first biopsy showed greater and faster granulation tissue formation process in the intervention group, so if the second biopsy was performed earlier probably more wounds contained mature granulation tissue in the intervention group. It seems that Albusite gel had a positive effect on wound healing acceleration which is not approved by histology and photography data. This is the first time that a combined histology criteria for wound healing is used, so it may help others to do better wound studies.

The present study had some advantages and limitations. The advantage of this study was that we did not dichotomize continuous variables data which has an additional impact on exactness. We acknowledge that only in two days histopathologic criteria were studied and this doesn't allow drawing any definitive conclusions. Therefore, a day-effects study is required for confirming the histology data.

## Conclusion

The healing and wound closure of Albusite treated wound was better than control wounds grossly but the authors suggest a new study with more rats and more frequent biopsy taking.

## Acknowledgment

We would like to express our sincere gratitude to Shiraz University of Medical Sciences animal House Manager Nader Tanideh, D.V.M, M.P.H and one of the Animal house staff, Omid Koochi and Also Vahid Hosseini M.D, Hamid Reza Forootan M.D, Saeid Marzban M.D and Ali Akbar Mohammadei M.D for their great guidance in using the procedure and methods.

This study was extracted from postgraduate thesis of Shahram Jahanabadi, M.D that was approved by Shiraz University of Medical Sciences. The authors would also like to thank Center for Development of Clinical Research of Nemazee Hospital and Dr. Nasrin Shokrpour for editorial assistance.

## Financial Disclosure

The authors declare that they have no competing interests.

## Funding/Support

There is no funding or supports.

## Author's Contributions

**Shahram Jahanabadi:** Designed the research plan and organized the study, participated in all experiments, coordinated the data-analysis.

**Mohammad Yasin Karami:** Participated in all experiments and data analysis.

**Shahram Paydar:** Participated in all experiments, data analysis and has drafted the article.

**Hamid Farzinnia:** Participated in all experiments and data analysis.

**Mohamed Amin Ghobadifar:** Participated in all experiments and data analysis.

**Nasrin Mansournia:** Participated in all experiments and data analysis.

**Mehrnoosh Maalhigh:** Participated in all experiments and data analysis.

## Ethics

This study was approved by the Ethical Committee of Shiraz University of Medical Sciences. No.93.215.429.

## References

- Abramov, Y., B. Golden, M. Sullivan, S.M. Botros and J.J. Miller *et al.*, 2007. Histologic characterization of vaginal vs. abdominal surgical wound healing in a rabbit model. *Wound Repair Regen*, 15: 80-86. PMID: 17244323
- Atiyeh, B.S., J. Ioannovich, C.A. Al-Amm and K.A. El-Musa, 2002. Management of acute and chronic open wounds: The importance of moist environment in optimal wound healing. *Curr. Pharm. Biotechnol.*, 3: 179-195. PMID: 12164477
- Brem, H., J. Balledux, T. Bloom, M.D. Kerstein and L. Hollier, 2000. Healing of diabetic foot ulcers and pressure ulcers with human skin equivalent: A new paradigm in wound healing. *Arch. Surg.*, 135: 627-34. PMID: 10843357
- Brem, H., T. Jacobs, L. Vileikyte, S. Weinberger and M. Gibber *et al.*, 2003. Wound-healing protocols for diabetic foot and pressure ulcers. *Surg. Technol. Int.*, 11: 85-92. PMID: 12931288
- Broughton, G., J.E. Janis and C.E. Attinger, 2006. The basic science of wound healing. *Plast. Reconstr. Surg.*, 117: 12S-34S. PMID: 16799372
- Brunnicardi, F., D. Andersen, T. Billiar, D. Dunn and J. Hunter *et al.*, 2009. *Schwartz's Principles of Surgery*, 9th Edn., Mc Graw Hill, New York, ISBN-10: 0071791590, pp: 1888.
- Dai, T., Y.Y. Huang, S.K. Sharma, J.T. Hashmi and D.B. Kurup *et al.*, 2010. Topical antimicrobials for burn wound infections. *Recent. Pat. Antiinfect. Drug Discov.*, 5: 124-151. PMID: 20429870
- Derici, H., E. Kamer, H.R. Unalp, G. Diniz and A.D. Bozdogan *et al.*, 2010. Effect of sildenafil on wound healing: An experimental study. *Langenbecks Arch. Surg.*, 395: 713-718. PMID: 19224243
- Diehr, S., A. Hamp and B. Jamieson, 2007. Do topical antibiotics improve wound healing? *Clin. Inquiries*, 56: 140-144.
- DiPietro, L.A., 2013. Angiogenesis and scar formation in healing wounds. *Curr. Opin. Rheumatol.*, 25: 87-91. DOI: 10.1097/BOR.0b013e32835b13b6
- Gethin, G., 2009. Role of topical antimicrobials in wound management. *J. Wound Care Activa Healthcare Supplement*.
- Golinko, M.S., S. Clark, R. Rennert, A. Flattau and A.J. Boulton *et al.*, 2009. Wound emergencies: The importance of assessment, documentation and early treatment using a wound electronic medical record. *Ostomy Wound Manage.*, 55: 54-61. PMID: 19471049
- Gross, R.L., 2000. The effect of ascorbate on wound healing. *Int. Ophthalmol. Clin.*, 40: 51-57. PMID: 11064856
- Hojati, H., K. Kazemi, N. Tanideh, E. Syvani and N. Roushan, 2004. The effect of egg yolk and gum tragacant ointment on wound healing: An experimental study on rabbits. *J. Med. Res.*, 2: 33-39.
- Kumar, V., A. Abbas, N. Fausto, S. Robbins and R. Cotran, 2005. Tissue renewal and repair: Regeneration, healing and fibrosis. *Pathologic Basis Dis.*, 7: 87-118.
- Lansky, E.P. and R.A. Newman, 2007. *Punica granatum* (pomegranate) and its potential for prevention and treatment of inflammation and cancer. *J. Ethnopharmacol.*, 109: 177-206. PMID: 17157465
- Leitch, I.O., A. Kucukcelebi and M.C. Robson, 1993. Inhibition of wound contraction by topical antimicrobials. *Aust. NZ J. Surg.*, 63: 289-293. PMID: 8311815
- Lessman, H., A. Schnuch, J. Geier and W. Uter, 2005. Skin-sensitization and irritant properties of propylene glycol. *Contact Dermatitis*, 53: 247-259. PMID: 16283903
- Lipsky, B.A. and C. Hoey, 2009. Topical antimicrobial therapy for treating chronic wounds. *Clin Practice*, 49: 1541-1549. DOI: 10.1086/644732
- McCauley, R.L., Y.Y. Li, V. Chopra, D.N. Herndon and M.C. Robson, 1994. Cytoprotection of human dermal fibroblasts against silver sulfadiazine using recombinant growth factors. *J. Surg. Res.*, 56: 378-384. PMID: 8152234
- Murphy, P.S. and G.R. Evans, 2012. Advances in wound healing: A review of current wound healing products. *Plast. Surg. Int.*, 2012: 190436. DOI: 10.1155/2012/190436

- Pirbalouti, A.G., S.H. Azizi, A. Koohpaye and B. Hamed, 2010. Wound healing activity of *Malva Sylvestris* and *Punica Granatum* in alloxan-induced diabetic rats. *Acta Pol. Pharm.*, 67: 511-516.  
PMID: 20873419
- Scardino, Swaim, Sartin, Hoffman and Oglivie *et al.*, 2002. The effects of omega-3 fatty acid diet enrichment on wound healing. *Vet. Dermatology*, 10: 283-290.  
DOI: 10.1046/j.1365-3164.1999.00148.x
- Schultz, G.S., R.G. Sibbald, V. Falanga, E.A. Ayello and C. Dowsett *et al.*, 2003. Wound bed preparation: A systematic approach to wound management. *Wound Repair Regeneration*, 11: S1-S28.  
DOI: 10.1046/j.1524-475X.11.s2.1.x
- Stadelmann, W.K., A.G. Digenis and G.R. Tobin, 1998. Physiology and healing dynamics of chronic cutaneous wounds. *Am. J. Surg.*, 76: 26S-38S.  
PMID: 9777970
- Sweetman, S.C., 2009. *Martindale: The Complete Drug Reference*. 36th Edn., Pharmaceutical Press, London, ISBN-10: 0853698406, pp: 3694.
- White, R.J., R. Cooper and A. Kingsley, 2001. Wound colonization and infection: The role of topical antimicrobials. *Br. J. Nurs.*, 10: 563-578.  
PMID: 12066030